















## Case report

### Lumbar Intradural intramedullary epidermoid cyst: a case report

*Cisto epidermóide intramedular intradural lombar: um relato de caso*

Andrey Maia Silva Diniz<sup>1</sup> , Otávio da Cunha Ferreira Neto<sup>2</sup> , Arthur Oliveira Lira<sup>3</sup> ,  
Melissa Helena Rodrigues Silva<sup>2</sup> , Maria Luísa Rocha<sup>4</sup> , Joaquim Fachine de Alencar Neto<sup>3</sup> ,  
Nilson Batista Lemos<sup>1</sup> , Luis Bandeira Alves Neto<sup>5</sup> , Luís Felipe Ferreira Marques<sup>6</sup> ,  
Luiz Severo Bem Junior<sup>7</sup> , Deoclides Lima Bezerra Júnior<sup>7</sup> , Geraldo de Sá Carneiro<sup>7</sup> ,  
Hildo Rocha Cirne de Azevedo Filho 

<sup>1</sup>Universidade Federal da Paraíba, João Pessoa, Paraíba, Brasil.

<sup>2</sup>Universidade Católica de Pernambuco, Recife, Pernambuco, Brasil.

<sup>3</sup>Centro Universitário Unifacisa, Campina Grande, Paraíba, Brasil.

<sup>4</sup>Centro Universitário de Brasília, Brasília, Distrito Federal, Brasil

<sup>5</sup>Universidade de Pernambuco, Recife, Pernambuco, Brasil.

<sup>6</sup>Universidade do Estado do Mato Grosso, Cáceres, Mato Grosso, Brasil.

<sup>7</sup>Departamento de Neurocirurgia, Hospital da Restauração, Recife, Pernambuco, Brasil.



Arthur Oliveira Lira  
artholira@gmail.com

**Edited by**  
Juliana Ramos de Andrade

**Palavras-chave:**  
Coluna vertebral  
Cisto epidermóide  
Neoplasia medular  
Relato de caso

**Keywords:**  
Spine  
Epidermoid cyst  
Spinal cord neoplasm  
Case report

#### Resumo

Os cistos epidermóides possuem etiologia benigna e podem ser congênitos, geralmente associados a malformações, ou adquiridos, relacionados a eventos externos, e até iatrogênicos. Quanto à sua localização, classificam-se em extradurais, intradurais, extramedulares e intramedulares. Os cistos epidermóides intramedulares intradurais são bastante incomuns, com poucos casos relatados na literatura até o momento. Devido ao seu desenvolvimento lento, pode haver atraso no diagnóstico. Seus sintomas dependem da topografia da lesão, sendo recomendada a remoção total do cisto para melhorar o quadro. Neste trabalho, relatamos o caso de um paciente adulto com paraparesia crural espástica progressiva, sem malformações associadas. Os exames de imagem mostraram um cisto epidermóide intradural intramedular, que foi completamente removido, com posterior melhora do quadro clínico do paciente.

#### Abstract

Epidermoid cysts have a benign etiology and can be either congenital, usually associated with malformations, or acquired, related to external events, and even iatrogenic. As for their location in the spine, they are classified as extradural, intradural, extramedullary, and intramedullary. Intradural intramedullary epidermoid cysts are quite uncommon, with few cases reported in literature so far. Because of its slow growth, there may be a delay in diagnosis. Its symptoms depend on lesion's topography, and total cyst removal is recommended to improve the condition. In this paper, we report the case of an adult patient with progressive spastic crural paraparesis, without associated malformations. Imaging exams showed an intradural intramedullary epidermoid cyst, which was completely removed, with subsequent improvement of patient's clinical status.

Submitted: November 18, 2022

Accepted: December 26, 2022

Published: December 29, 2022

## Introduction

Epidermoid tumors are benign lesions without specific clinical symptoms, arising from the ectopic development of epidermal cells that accumulate keratin. These lesions are rarely found in spine, being more common in the skull<sup>1</sup> and, depending on their topography, generate symptoms due their growth.

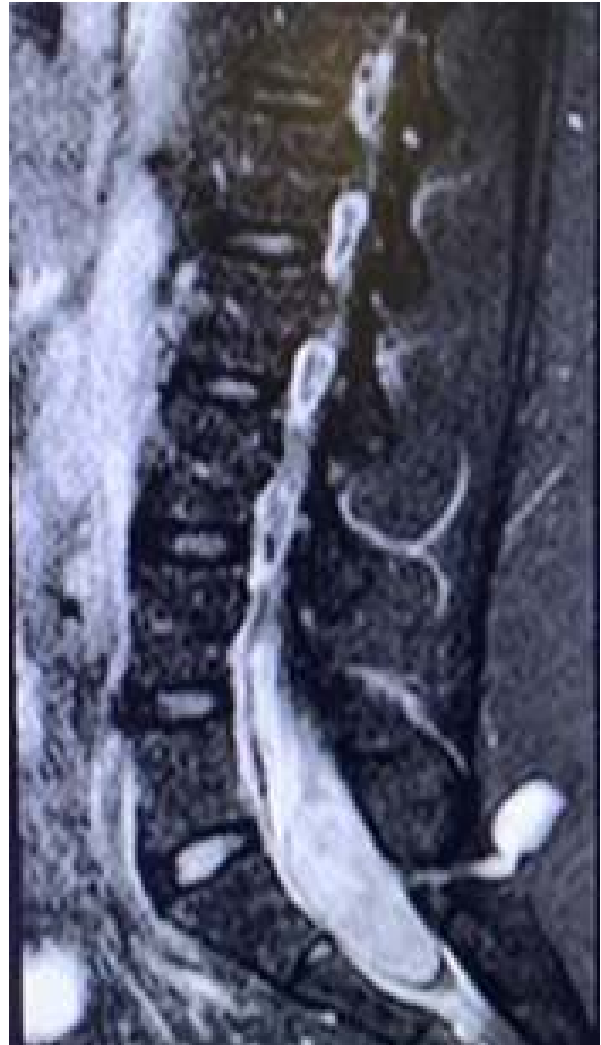Its classification is divided into two types: congenital and acquired. Congenital cysts are already established in the individual from birth and are commonly associated with other spinal defects<sup>1</sup>. Acquired cysts, on the other hand, occur when epidermal cells are implanted inside the spinal canal by external events, such as gunshot wounds, or medical procedures, such as anesthesia.<sup>2</sup>

As for location, they can be extradural, intradural, extramedullary and intramedullary, with most of them classified as intradural extramedullary<sup>2</sup>. The aim of this study is to report the case of an intradural intramedullary epidermoid cyst in an adult patient.

## Case report

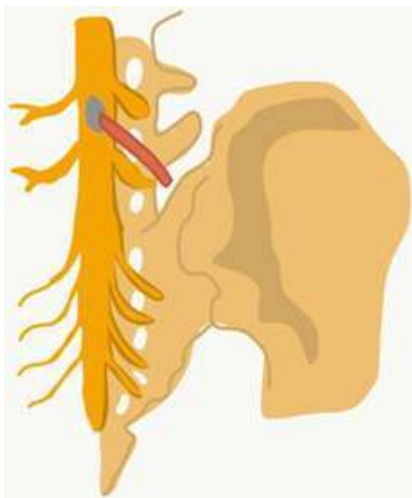
A 24-year-old female patient was admitted to the emergency department of a public neurological surgery reference hospital in Pernambuco, Brazil, complaining of low back pain, beginning 3 months ago, and persistent urinary retention, using an indwelling urinary catheter. The patient's medical history does not contain information about previous malformation, lumbar puncture, trauma or neurosurgery.

On physical examination, she presented symmetrical spastic crural paraparesis with grade IV motor strength in all muscle groups, with sensitivity preserved bilaterally. Magnetic Resonance Imaging (MRI) of lumbosacral spine showed an expansible, homogeneous, intradural lesion at the level of L5 and S1, occupying the topography of cauda equina, with hyposignal on T1-weighted MRI scan (Figure 1).

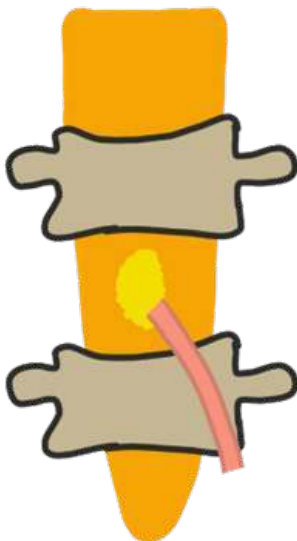


**Figure 1.** 24-year-old female with intradural epidermoid cyst who presented with low back pain and urinary retention. Contrast-enhanced MRI image showing well-defined lesion, no perilesional edema, with a thin rim of capsular enhancement. A fistulous tract was identified connecting the intramedullary component to the subcutaneous tissue with contrast uptake (without externalization to the external environment).

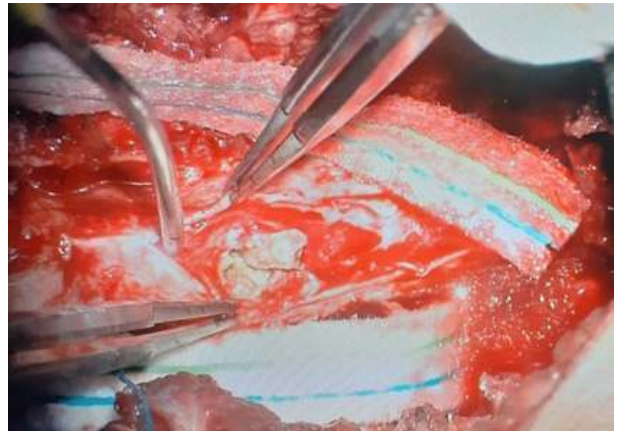
The patient was positioned in prone position and a median incision was made. In the subcutaneous region, a fistulous tract was identified, not communicating with the external environment and with no secretion (Figures 2 and 3). A block laminectomy was performed by posterior approach for complete resection of lesion. Intraoperatively, a softened, pearly-colored, hairy, shiny and fatty lesion was observed (Figure 4) occupying the transition region between the lumbar and sacral spinal cord, which was completely resected by microsurgical technique. During the surgery, motor potential evoked were compatible with first motor neuron fibers distal to the described cystic lesion, showing its intramedullary component.



**Figure 2.** Schematic drawing showing the fistulous tract, in red, that communicates the intramedullary component to the subcutaneous tissue.



**Figure 3.** Schematic drawing showing the fistulous, in red, tract that communicates the intramedullary component to the subcutaneous tissue.



**Figure 4.** 24-year-old female with intradural epidermoid cyst who presented with low back pain and urinary retention. Intraoperative image showing brownish lesion, with hairy e sebaceous findings.

The anatomopathological exam confirmed an epidermoid cyst, containing brownish squamous epithelium and a large amount of irregularly stratified keratin. Postoperatively, the patient presented worsening of motor strength in the lower limbs and urinary retention, with subsequent improvement of her clinical status in three weeks through physiotherapy.

## Discussion

Epidermoid cysts are benign lesions that accumulate keratin and are lined by stratified squamous epithelium<sup>1</sup>, accounting for less than 1% of all intraspinal tumors, and are rare in adult population.<sup>2</sup> True intramedullary epidermoid cysts are even more uncommon, with less than 60 cases reported in literature from the first report until 2009.<sup>3</sup> Between 2009 and 2022, approximately 30 cases of intramedullary epidermoid cyst were reported according to the PubMed database. Despite these new reports, the evaluation and prognosis of the epidermoid cyst has not changed overtime, with an early diagnosis and a surgical approach to remove the cyst prevailing.

They are mainly congenital, as they originate from anomalous inclusion of the ectoderm during neural tube closure early in fetal life.<sup>4</sup> In this variation, there is usually an association with spinal dysraphic states, such as Syringomyelia, dermal sinus or spina bifida.<sup>1</sup> Acquired cysts, on the other hand, are usually associated with iatrogeny, such as repeated lumbar punctures<sup>1,2</sup>, causing the penetration of small skin fragments. Since there are no reports of external events, such as invasive medical procedure, this is a congenital cyst, although the patient has no associated malformation.

Magnetic resonance imaging revealed a fistulous path that

connected the intramedullary region with the subcutaneous region (Figure 1). In this sense, this fistulous tract is a congenital cause of the formation of the epidermoid cyst<sup>1</sup>, since the patient denies any medical condition that explain an acquired cause for the cyst source, such as medical iatrogenesis in repeated lumbar puncture.

The symptoms vary according to the degree of spinal involvement and occur as a result of cyst's expansion within spinal canal. Patients with this lesion may present progressive paraparesis, sensory loss, urological manifestations and leg pain, and the manifestation of these symptoms is gradual, since the cyst presents a slow growth, sometimes even delaying the diagnosis.<sup>2</sup> In the reported case, patient's physical examination findings converge with literature, as she presented spastic crural paraparesis, in addition to having urological damage associated with the lesion.

Magnetic resonance imaging (MRI) is the exam that diagnoses spinal epidermoid cysts. On T1 and T2-weighted MRI, the lesion can range from hypo to isointense, with hyperintensity occasionally seen on T2 weighted images.<sup>5,6</sup> Other important findings include the absence of edema in peripheral tissue, presence of well-defined boundaries and peripheral enhancement on injection of gadolinium.<sup>7</sup> Histologically, a cyst lined by a stratified squamous epithelium is observed, supported by an external layer of collagen<sup>2</sup>, which differs from the reported case since the keratin was irregularly stratified.

Treatment is essentially surgical<sup>7</sup> and, if possible, aims to completely remove the cyst, so that symptoms can be completely resolved.<sup>2</sup> Caution is required during removal, since the capsule may be firmly attached to adjacent structures, which can cause neurological damage if total removal is chosen, and should be avoided in these cases.<sup>2</sup> In the case described the improvement of symptoms after surgical resection converges with literature as the patient had a good evolution after 3 weeks.

## Conclusion

Intradural epidermoid cysts are quite rare, and their intramedullary variable is even more uncommon. Because of its slow growth, there may be a delay in diagnosis due to the slow progression of symptoms, which may sometimes be nonspecific. Although benign, its diagnosis should be made as early as possible, to avoid further neurological damage and improve its prognosis.

Andrey Maia Silva Diniz  
<https://orcid.org/0000-0002-5572-7018>  
Otávio da Cunha Ferreira Neto

<https://orcid.org/0000-0003-0517-0212>  
Arthur Oliveira Lira  
<https://orcid.org/0000-0002-5746-5728>  
Melissa Helena Rodrigues Silva  
<https://orcid.org/0000-0001-9846-3801>  
Maria Luísa Rocha  
<https://orcid.org/0000-0001-8717-2363>  
Joaquim Fachine de Alencar Neto  
<https://orcid.org/0000-0003-2042-4874>  
Nilson Batista Lemos  
<https://orcid.org/0000-0002-2331-6871>  
Luis Bandeira Alves Neto  
<https://orcid.org/0000-0003-3245-1036>  
Luís Felipe Ferreira Marques  
<https://orcid.org/0000-0001-7461-8637>  
Luiz Severo Bem Junior  
<https://orcid.org/0000-0002-0835-5995>  
Deoclides Lima Bezerra Júnior  
<https://orcid.org/0000-0002-6493-350X>  
Geraldo de Sá Carneiro  
<https://orcid.org/0000-0002-5518-317X>  
Hildo Rocha Cirne de Azevedo Filho  
<https://orcid.org/0000-0002-1555-3578>

### Conflict of interest

The authors declares that there is no conflict of interest regarding the publication of this paper.

### Funding

The authors declare that neither the research nor the publication of this paper was funded by any financially supporting bodies.

### Authors contribution

AMSD, OCFN, DLBJ, GSC, HRCAF, conceptualization; AMSD, OCFN, methodology, validation; AMSD, OCFN, AOL, MHRS, MLR, JFAN, NBL, LBAN, LFFM, LSBJ, DLBJ, GSC, HRCAF, formal analysis, investigation, resources, Writing Original Draft. AMSD, DLBJ, GSC, HRCAF: Project administration; AMSD, OCFN, DLBJ, GSC, HRCAF: Supervision; AOL, MHRS, LFFM, LSBJ: Data curation; AOL, MHRS, MLR, JFAN, NBL, LBAN, LFFM, LSBJ: Writing-Review & Editing.

## References

1. Musali SR, Mohammed I, Gollapudi PR and Maley SK. **Dorsal Spinal Intradural Intramedullary Epidermoid Cyst: A Rare Case Report and Review of Literature.** *J Neurosci Rural Pract* 2019;10(2):352-354 Doi:10.4103/jnrp.jnrp\_304\_18
2. Gotecha S, Ranade D, Sharma S, Punia P and Kotecha M. **Giant intradural intramedullary epidermoid cyst Report of two cases with varied presentations.** *Asian J Neurosurg* 2014;9(4):244 Doi:10.4103/1793-5482.146653

3. Gonzalvo A, Hall N, McMahon JH and Fabinyi GC. **Intramedullary spinal epidermoid cyst of the upper thoracic region.** *J Clin Neurosci* 2009;16(1):142-144 Doi:10.1016/j.jocn.2008.04.017
4. Kumar A, Singh P, Jain P and Badole CM. **Intramedullary spinal epidermoid cyst of the cervicodorsal region: A rare entity.** *J Pediatr Neurosci* 2010;5(1):49-51 Doi:10.4103/1817-1745.66675
5. Gupta S, Gupta RK, Gujral RB, Mittal P, Kuriyal M and Krishnani N. **Signal intensity patterns in intraspinal dermoids and epidermoids on MR imaging.** *Clin Radiol* 1993;48(6):405-413 Doi:10.1016/s0009-9260(05)81110-9
6. Visciani A, Savoiaro M, Balestrini MR and Solero CL. **Iatrogenic intraspinal epidermoid tumor: myelo-CT and MRI diagnosis.** *Neuroradiology* 1989;31(3):273-275 Doi:10.1007/bf00344358
7. Chandra PS, Manjari T, Devi BI, Chandramouli BA, Srikanth SG and Shankar SK. **Intramedullary spinal epidermoid cyst.** *Neurol India* 2000;48(1):75-77