
















Case Report

Falcotentorial meningiomas: Optimal surgical planning and intraoperative challenges – case report

Otávio da Cunha Ferreira Neto¹ , Pedro Lukas do Rêgo Aquino² , Marcelo Diniz de Menezes³ ,
Nilson Batista Lemos⁴ , Bianca Domiciano Vieira Costa Cabral⁵ , João Ricardo Caldas Pinheiro Pessoa¹ ,
Andrey Maia Silva Diniz⁵ , Artêmio José Araruna Dias⁴ , Luís Felipe Gonçalves de Lima⁴ ,
Luiz Euripedes Almondes Santana Lemos⁶ , Luiz Severo Bem Junior^{4,6} , Nivaldo Sena de Almeida⁶ ,
Hildo Rocha Cirne Azevedo Filho⁶ 

¹Catholic University of Pernambuco (UNICAP), Recife, PE, Brasil

²University of Pernambuco (UPE), Recife, PE, Brasil

³Faculdade Pernambucana de Saúde (FPS), Recife, PE, Brasil

⁴College of Medical Sciences, Unifacisa University Center (UNIFACISA), Campina grande, PB, Brasil

⁵Federal University of Paraíba (UFPB), João Pessoa, PB, Brasil

⁶Department of Neurosurgery, Hospital da Restauração, Recife, PE, Brasil



Otávio da Cunha Ferreira Neto
otavioferreiraneto@gmail.com

Editado por
Juliana Ramos Andrade

Keywords:
Falcotentorial meningioma
Occipital transtentorial approach
Pineal region meningioma
Third Ventricle

Abstract

Meningiomas arising from the falcotentorial junction are rare, and selecting the optimal surgical approach is essential. We report a 41-year-old man presented with progressive left paresis in the lower limbs. A magnetic resonance image showed a solid mass inside the third ventricle in contact with the falcotentorial dural junction. The tumor was removed by the transtentorial/transfalxine occipital approach, performed with the patient in the three-quarter prone position. The tumor was devascularized from the tentorium, then debulked and finally dissected. The affected falx and tentorium were resected, but all of the patent dural venous sinuses were preserved. The tumor was a subtotal resect. Choosing the surgical approach is essential for the safe and effective removal of an falcotentorial meningioma and preoperative imaging analysis should identify the tumor's anatomical relations and guide toward the least disruptive route that preserves the neurovascular structures. This article aims to report a successfully treated a falcotentorial meningioma.

Introduction

Among pineal region tumors, meningiomas are a rare entity, corresponding to 2-8% of pineal tumors and 1% of all intracranial meningiomas.¹⁻³ Guttman described the first pineal meningioma in 1930.⁴ These tumors originate from the posterior portion of the *velum interpositum* or falcotentorial union.³

Falcotentorial meningiomas (FTM), as with other pineal region tumors, are prevalent more in females.³ These tumors can present a different relationship with vital neuroanatomical structures; therefore, it is essential to decide the ideal surgical approach. It is often difficult to discriminate between FTM and *velum interpositum* meningiomas, even after significant advances in neuroimaging.³ However, arterial irrigation is the main difference between these two groups of tumors. The tentorial branches of the meningohypophyseal trunk usually supply FTMs, while branches of the posterior choroidal arteries irrigate *velum interpositum* meningiomas.^{3,6} The surgical treatment of these tumors is not well established in literature since there are two main controversial issues. Firstly, concerning validating criteria for selecting the optimal surgical approach, and secondly, whether the main infiltrated venous structures can be sacrificed to obtain a radical resection of the tumor or whether they should be preserved.⁶

We report an FTM case approached by occipito-trans-tentorial access and subtotal tumor resection presenting a satisfactory clinical outcome.

Case Report

A 41-year-old man, with no significant medical history, was admitted with progressive paresis in the left lower limb, which started one year earlier and deteriorated in the final 3 months and no other neurological alterations were found. A computed tomography (CT) scan revealed a solid mass in the pineal region, causing hydrocephalus. A ventricle-peritoneal shunt was performed as a primary hydrocephalus treatment. Posteriorly, brain magnetic resonance imaging (MRI) showed a solid mass inside the third ventricle in contact with the falcotentorial dural junction, 42 x 43 x 38 mm in diameter, hypointense in T1 and slight hyperintense in T2 sequences, with diffusion restriction and enhancement post gadolinium (Figure 1). It was minimally lateralized to the right side, with inferior displacement of the deep venous complex of Galen.

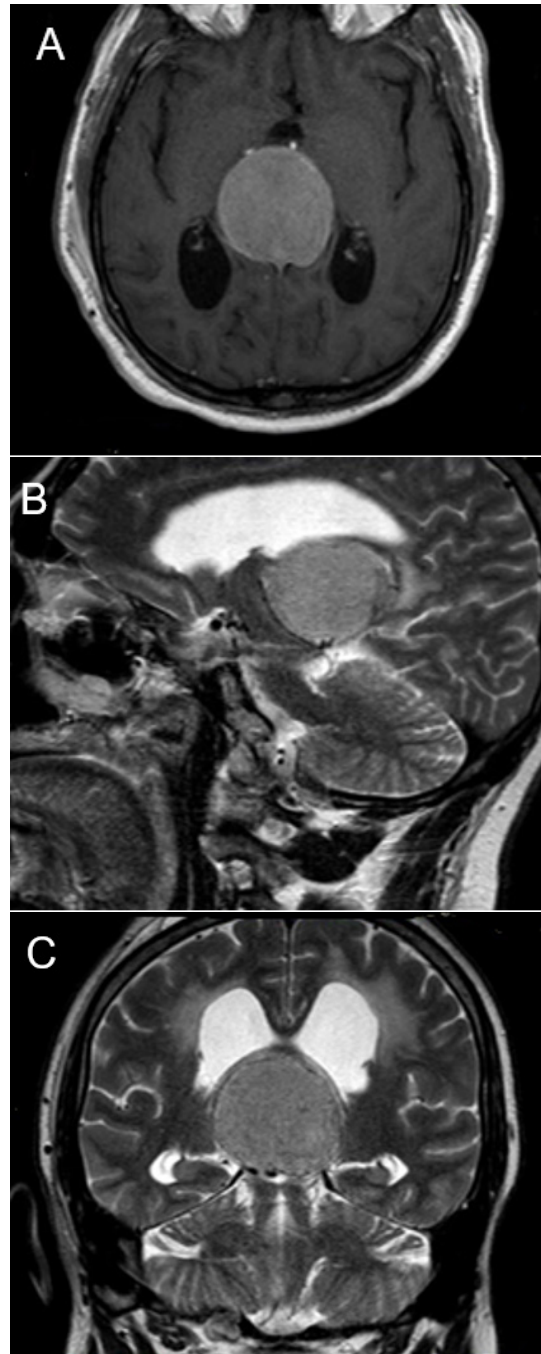

Figure 1. Preoperative axial T1 (A), sagittal T2 (B) and coronal (C) T2 MR images showing the pineal region meningioma, 42 x 43 x 38 mm in diameter, hypointense in T1 and hyperintense in T2 sequences, with the deep venous system displaced inferiorly.

The patient underwent a transtentorial/transfalciine occipital surgical approach in a three-quarter prone position. The patient's head was slightly elevated to 15 degrees in relation to the floor and turned 60 degrees toward the floor (Figure 2). The tumor was larger on the right side, and that side was

chosen for a surgical approach. Firstly, the tumor was devascularized from the tentorium, then debulked and finally dissected. The affected falx and tentorium were resected, but all the patent dural venous sinuses were preserved. The tumor underwent a subtotal resection (Figure 3).




Figura 2. Transtentorial/transfalciine occipital surgical approach in three/quarter prone position and the patient head fixed in Mayfield.

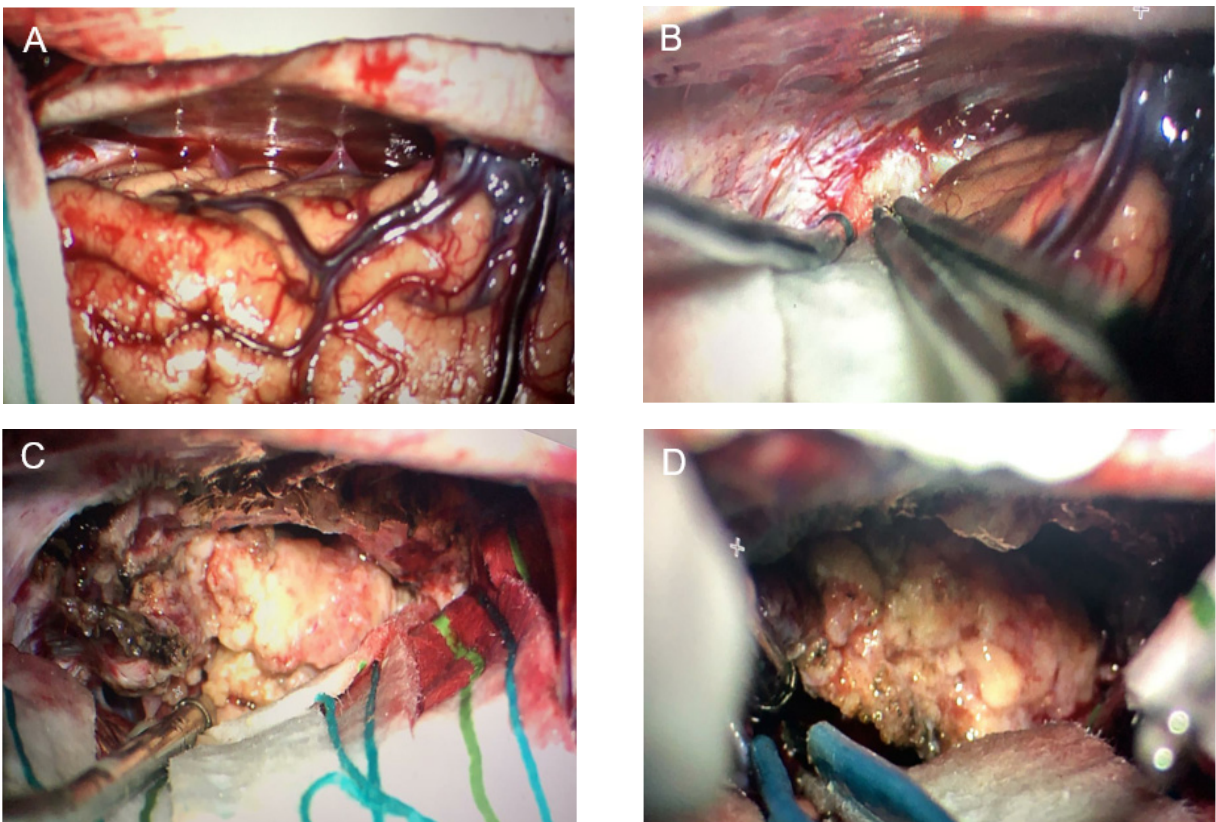
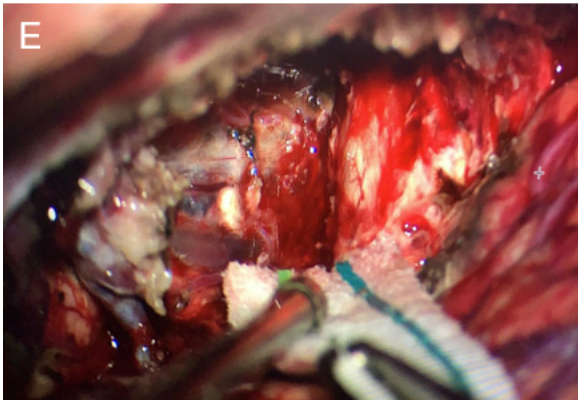


Figura 3. A. Opening of the interhemispheric fissure through the right transtentorial/transfalciine occipital approach; B. Interhemispheric retraction reveals the tumor in a posterior incisural space; C-D. Tumor devascularization from the tentorium and resection; and E. Operative cavity. (Continued on next page)



The patient presented superior temporal homonymous quadrantanopia in the immediate postoperative period and after permanently. The post-surgery CT revealed hypointense imaging in occipital-parietal artery supply region, suggesting ischemia and a small pneumocephalus (Figure 4). The patient is under ambulatory follow-up in the last three months, without other neurological symptoms. After, an anatomopathologic study demonstrated a WHO grade I meningothelial meningioma.

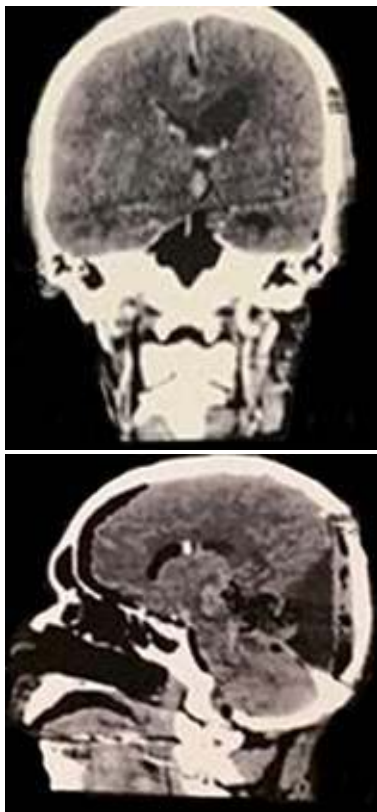


Figura 4. The post-surgery computed tomography revealing surgical complications.

Discussion

FTMs occurs mostly in patients between 42-56 years old as well as the posterior fossa meningiomas.⁷ Previously studies revealed headaches as the most common symptom in pineal region meningiomas (60 to 100% of the cases), followed by ataxia (43 to 62%), personality changes and bradypsychia (37 to 46%) with homonymous hemianopia (20 to 46%).⁴

Ataxia is the most frequent late symptom in type I and II tumors. Personality changes and bradypsychia were mostly associated on obstructive hydrocephalus cases.⁴ Nevertheless, bilateral visual acuity deterioration due to progressive papilledema and the following atrophy of the optic nerve is extremely rare.⁸

In 2008, Bassiouni et al. classified FMTs tumors according to tumor base location and included four types.⁶ In our case, the FTM originated from the posterior cerebral falx and displaced the venous system inferiorly, type I by the Boussioni classification.

Regarding surgical treatment, comprehending the relationship between meningiomas of the pineal region and the deep venous system is decisive for better results. Invasive tumor degree or the permeability of the vein of Galen and the straight sinus and the displacement of these vessels are relevant points in view of the tumor's mass effect.^{7,9}

The vein of Galen and straight sinus occlusion and invasion were described in preoperative angiographic studies; consequently, the development of a secondary collateral venous drainage is frequently found.^{7,9} It can be explained because the posterior half of the vein of Galen and the anterior half of the straight sinus is mostly the first vessels affected by meningiomas and are not related to the tumor's growth direction.

Identifying vessel occlusion and the secondary collateral venous drainage is essential to evaluate the optimal FTMs surgical planning.^{7,8} Many authors have proposed that the displacement of the deep venous system due to tumor growth direction is the most important characteristic when deciding the surgical approach.^{1,2,4,6} Therefore, Type I of FTMs displace the venous complex inferiorly, type II superiorly, type III medially (supero-/inferomedial), and type IV to the contralateral side of the meningioma.⁴

FTMs surgical objective is to achieve a macroscopically complete resection of the lesion, to relieve or solve the neu

rologic/clinical symptoms, and to acquire a tissue sample for a definitive diagnosis. Therefore, the recommendation to perform an intraoperative biopsy is established, paving the way to obtaining a differential diagnosis from other pineal tumors (e.g., germinoma) for which the management may be different toward a partial resection after adjuvant therapy.¹⁰

Classically, for preoperative artery embolization is an important adjuvant treatment for meningioma. However, most FTMs present short artery caliber, which can difficult preoperative artery embolization.⁷

The anatomical relation between the tumor and the deep venous complex of Galen is the most important factor when choosing the surgical approach. Some surgical approaches are described for these tumors: transtentorial/transfalci-occipital approach, supracerebellar infratentorial approach, occipital bitransfalcine approach and anterior interhemispheric transsplenic approach.

Transtentorial/Transfalci Occipital Approach. It was used in our case, and it is the most frequently used for pineal meningiomas. This approach is more specifically advised in type I and IV FTMs, which originate from posterior falx immediately above the vein of Galen and straight sinus junction. In this location, the tumor's growth displaces posterior and inferiorly the deep venous complex.

This approach is used to reach tumors with a mostly supratentorial and a smaller infratentorial extension. The occipital lobe is also gravity-dependent positioned bearing the largest component of the tumor. In this present case, we consider this information to be an important feature in our surgical approach choice. However, this surgical approach has some disadvantages such as an increased risk of visual cortex damage (due to cortex retraction), possible trochlear nerve damage at the tentorial opening and a limitation of the contralateral view of the tumor margin.

Conclusion

The selection of an optimal surgical approach is essential for the safe and effective removal of an FTM. Preoperative imaging analysis should identify the tumor's anatomical relations and guide the least disruptive route that preserves the neurovascular structures. This article aims to report a successfully treated FTM at our service and to serve as a literary review. Subtotal resections appear to reduce severe neurological deficit rates, thus, being beneficial in most cases such as ours.

Otávio da Cunha Ferreira Neto
<https://orcid.org/0000-0003-0517-0212>
 Pedro Lukas do Rêgo Aquino
<https://orcid.org/0000-0002-1244-8641>
 Marcelo Diniz de Menezes
<https://orcid.org/>
 Nilson Batista Lemos
<https://orcid.org/0000-0002-2331-6871>
 Bianca Domiciano Vieira Costa Cabral
<https://orcid.org/0000-0001-7725-0524>
 João Ricardo Caldas Pinheiro Pessôa
<https://orcid.org/0000-0002-0612-6478>
 Andrey Maia Silva Diniz
<https://orcid.org/0000-0002-5572-7018>
 Artêmio José Araruna Dias
<https://orcid.org/0000-0002-3565-0586>
 Luís Felipe Gonçalves de Lima
<https://orcid.org/0000-0002-0130-0625>
 Luiz Euripedes Almondes Santana Lemos
<https://orcid.org/0000-0001-5334-004X>
 Luiz Severo Bem Junior
<https://orcid.org/0000-0002-0835-5995>
 Nivaldo Sena de Almeida
<https://orcid.org/>
 Hildo Rocha Cirne Azevedo Filho
<https://orcid.org/0000-0002-1555-3578>

Referências

- Behari S, Das KK, Kumar A, Mehrotra A, Srivastava AK, Sahu RN and Jaiswal AK. **Large/giant meningiomas of posterior third ventricular region: falcotentorial or velum interpositum?** *Neurol India* 2014;62(3):290-295 Doi:10.4103/0028-3886.136934
- Hong CK, Hong JB, Park H, Moon JH, Chang JH, Lee KS and Park SW. **Surgical Treatment for Falcotentorial Meningiomas.** *Yonsei Med J* 2016;57(4):1022-1028 Doi:10.3349/ymj.2016.57.4.1022
- Yaşar S and Kırık A. **Surgical Management of Giant Intracranial Meningiomas.** *Eurasian J Med* 2021;53(2):73-78 Doi:10.5152/eurasianjmed.2021.20155
- Guttman E. **Zur pathologie und Klinik der Meningiome.** *J Zeitschrift Neurol und Psych* 1930;123(1):606-625
- Ito J, Kadekaru T, Hayano M, Kurita I, Okada K and Yoshida Y. **Meningioma in the tela choroidea of the third ventricle: CT and angiographic correlations.** *Neuroradiology* 1981;21(4):207-211 Doi:10.1007/bf00367342
- Bassiouni H, Asgari S, König HJ and Stolke D. **Meningiomas of the falcotentorial junction: selection of the surgical approach according to the tumor type.** *Surg Neurol* 2008;69(4):339-349; discussion 349 Doi:10.1016/j.surneu.2007.02.029
- Quiñones-Hinojosa A, Chang EF, Chaichana KL and McDermott MW. **Surgical considerations in the management of**

- falcotentorial meningiomas: advantages of the bilateral occipital transtentorial/transfalciine craniotomy for large tumors.** *Neurosurgery* 2009;64(5 Suppl 2):260-268; discussion 268 Doi:10.1227/01.Neu.0000344642.98597.A7
8. Asari S, Maeshiro T, Tomita S, Kawauchi M, Yabuno N, Kinugasa K and Ohmoto T. **Meningiomas arising from the falcotentorial junction. Clinical features, neuroimaging studies, and surgical treatment.** *J Neurosurg* 1995;82(5):726-738 Doi:10.3171/jns.1995.82.5.0726
9. Sekhar LN and Goel A. **Combined supratentorial and infratentorial approach to large pineal-region meningioma.** *Surg Neurol* 1992;37(3):197-201 Doi:10.1016/0090-3019(92)-90230-k
10. Sung DI, Harisiadis L and Chang CH. **Midline pineal tumors and suprasellar germinomas: highly curable by irradiation.** *Radiology* 1978;128(3):745-751 Doi:10.1148/128.3.745