



## Case Report

### Bilateral abducens nerve palsy after a rupture of an anterior communicating artery aneurysm: a case report

Luiz Severo Bem Junior<sup>1,3</sup> , Otávio da Cunha Ferreira Neto<sup>2</sup> , Melissa Helena Rodrigues Silva<sup>2</sup> ,  
Joaquim Fachine de Alencar Neto<sup>1</sup> , Nilson Batista Lemos<sup>1</sup> , Victor Marcus de Menezes Lima Correia<sup>2</sup> ,  
Luís Felipe Gonçalves de Lima<sup>1</sup> , Artêmio José Araruna Dias<sup>1</sup> , Victor Egypto Pereira<sup>4</sup> ,  
Nivaldo Sena Almeida<sup>3</sup> , Hildo Rocha Cirne de Azevedo Filho<sup>3</sup> 

<sup>1</sup>Unifacisa Centre University, Campina Grande, Brazil

<sup>2</sup>Catholic University of Pernambuco, Recife, Brazil

<sup>3</sup>Department of Neurosurgery, Hospital da Restauração, Recife, Brazil

<sup>4</sup>Post Program Health Sciences Applied to the Locomotor System, Sao Paulo University, Ribeirão Preto, Brazil



Luiz Severo Bem Junior  
luizseverobemjunior@gmail.com

#### Edited by

Juliana Ramos de Andrade

#### Keywords:

VI cranial nerve  
Cerebral aneurysm  
Paralysis  
Anterior communicating artery

#### Abstract

A rare case of bilateral abducens nerve palsy occurred in a 60-year-old man hospitalized after a sudden severe headache and horizontal binocular diplopia. The patient did not present other neurological manifestations. A computed tomography (CT) revealed a subarachnoid hemorrhage, and the arteriography showed an anterior communicating artery (ACoA) aneurysm. After the aneurysm embolization, the patient continues to evolve with maintenance of the condition. Bilateral abducens nerve palsy can occur due to several factors, but its pathophysiology associated with the rupture of aneurysms in ACoA has several gaps in knowledge and scarce literary support. Thus, the need for studies in this field is pointed.

Received: December 16, 2021

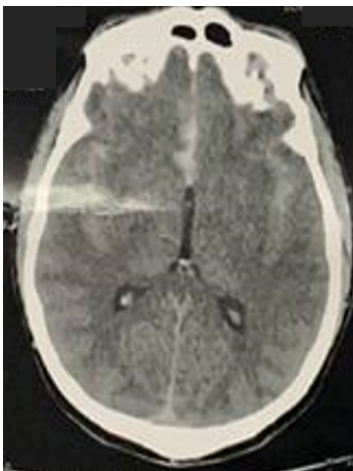
Accepted: April 20, 2022

## Introduction

The abducens nerve is the sixth nerve of the cranial pairs responsible for the ipsilateral abduction of the eyes. It originates from the pontomedullary junction, crosses between the anterior inferior cerebellar artery (AICA) and labyrinthine artery, and passes through the prepontine cistern, Dorello's canal, cavernous sinus, superior orbital fissure, and orbita respectively.<sup>1,2</sup> Bilateral paresis of this nerve can have multiple causes, such as intracranial hypertension, encephalopathy, and tumors, among others. Its isolated association with the rupture of an anterior communicating artery (ACoA) aneurysm is quite rare, and this mechanism is responsible for 3.3 to 3.6% of the cases.<sup>3</sup> Sudden onset of bilateral abducens nerve palsy related to ACoA aneurysmal rupture is very rare and we report a rare case of a patient who presented bilateral horizontal ophthalmoparesis of the abducens nerve after subarachnoid hemorrhage due to rupture of the ACoA aneurysm and discuss the potential related mechanisms.

## Case Report

A 60-year-old man with arterial hypertension was admitted to the hospital with a sudden headache and binocular horizontal diplopia. On neurological examination, Glasgow coma scale (GCS) 13, pupils reactive and isochoric, bilateral abducens nerve palsy, no motor deficits and no nuchal rigidity. Computed tomography (CT) showed a subarachnoid hemorrhage (Figure 1) level 3 on the Fischer scale, and arteriography revealed ACoA aneurysm. The patient underwent aneurysm embolization and continues to evolve the maintenance of bilateral horizontal ophthalmoparesis of the abducens nerve.



**Figure 1.** Computed tomography shows a subarachnoid hemorrhage, due to rupture of anterior communicating artery aneurysm.

## Discussion

The mechanisms related to bilateral abducens nerve palsy after ACoA aneurysm rupture are not yet clearly established, but some hypotheses are proposed to elucidate them. It is speculated to be intracranial hypertension caused by cerebral edema or intraparenchymal hemorrhage, nerve compression by a clot in the prepontine cistern, vasospasm of the pontine branches of the basilar artery, damaging the abducens nuclei, all of which may compress some area of the nerve.<sup>4</sup>

There are few records associating a panorama of anterior communicating artery rupture with abducens nerve palsy among the reported cases in the literature. It is known that visual field defects are often associated with involvement of the internal carotid artery and anterior communicating artery ACoA (due to the location of the nerve and the optic chiasm), while eye movement has disorders more associated with basilar aneurysms, as well as with the internal carotid artery.<sup>5</sup> Most problems associated with eye movement are attributed to unruptured aneurysms because of the compressive effect on nerve structures, in addition to the fact that most manifestations are unilateral paralysis.<sup>5</sup>

After the CT scan of our patient, two mechanisms were proposed: intracranial hypertension without classic clinical manifestations, this being one of the factors that can readily trigger paralysis or direct compression of the abducens nerve by a clot in the prepontine cistern. Within the researched hypotheses, the etiology resulting from vasospasm was also considered. This case report is carried out with the aim of identifying the connexion between bilateral abducens nerve palsy and rupture of an ACoA aneurysm and its possible causes and consequences. Today, we have a few cases reported in the literature. Thus, it emphasizes the need for further studies on this topic to resolve this impasse, as well as to establish appropriate treatment strategies.

## Conclusion

Finally, it is possible to note the complexity involving the pathophysiology and the vasculonervous dynamics associated with the sixth cranial pair paralysis reported in the article. Thus, in view of the small number of reported cases of this event secondary to aneurysm rupture, the understanding of this condition is still very limited, highlighting the need for further studies on this theme to solve this impasse, as well as to establish appropriate treatment strategies.

### Acknowledgments

We are grateful to the masters of Hospital da Restauração who provided insight and expertise that greatly assisted the research and actively stimulated the search for answers.

### Data Availability

All data generated or analysed during this study are included in this published article.

### Conflicts of Interest

The authors declare that there is no conflict of interest regarding the publication of this paper.

### Funding Statement

The authors declare that neither the research nor the publication of this paper was funded by any financially supporting bodies.

**Authors' contributions:** LSBJ, Conceptualization, Method, Validation, Formal analysis, Investigation, Resources, Writing-Original Draft, Supervision. OCFN, MHRs, JFAN, NBL, VMMLC, LFGL, AJAD, VEP, NSA, Data curation, Writing-Original draft, Investigation, Formal analysis, Resource, Writing-Review & Editing. and HRCAF, Conceptualization, Validation, Formal analysis, Resources, Project administration, Supervision., Project administration, Supervision.

Luiz Severo Bem Junior

<https://orcid.org/0000-0002-0835-5995>

Otávio da Cunha Ferreira Neto

<https://orcid.org/0000-0003-0517-0212>

Melissa Helena Rodrigues Silva

<https://orcid.org/0000-0001-9846-3801>

Joaquim Fechine de Alencar Neto

<https://orcid.org/0000-0003-2042-4874>

Nilson Batista Lemos

<https://orcid.org/0000-0002-2331-6871>

Victor Marcus de Menezes Lima Correia

<https://orcid.org/0000-0002-2786-4189>

Luís Felipe Gonçalves de Lima

<https://orcid.org/0000-0002-0130-0625>

Artêmio José Araruna Dias

<https://orcid.org/0000-0002-3565-0586>

Victor Egypto Pereira

<https://orcid.org/0000-0002-4764-6402>

Nivaldo Sena Almeida

<https://orcid.org/0000-0003-0925-8473>

Hildo Rocha Cirne de Azevedo Filho

<https://orcid.org/0000-0002-1555-3578>

## References

1. Alalwi S, Alabbadi A, Alomair AM and Alfaraj D. **Transient Bilateral Sixth Nerve Palsy: A Rare Sequela of Head Trauma.** *Cureus* 2021;13(1):e12805 Doi:10.7759/cureus.12805
2. Göksu E, Akyüz M, Gürkanlar D and Tuncer R. **Bilateral abducens nerve palsy following ruptured anterior communicating artery aneurysm: report of 2 cases.** *Neurocirugía* 2007;18(5):420-422 Doi:10.1016/s1130-1473(07)70269-5
3. Ziyal IM, Ozcan OE, Deniz E, Bozkurt G and Ismailoglu O. **Early improvement of bilateral abducens nerve palsies following surgery of an anterior communicating artery aneurysm.** *Acta Neurochir* 2003;145(2):159-161 Doi:10.1007/s00701-002-1041-3
4. Jeon JS, Lee SH, Son Y-J and Chung YS. **Slowly Recovering Isolated Bilateral Abducens Nerve Palsy after Embolization of Ruptured Anterior Communicating Artery Aneurysm.** *J Korean Neurosurg Soc* 2013;53(2):112-114 Doi:10.3340/jkns.2013.53.2.112
5. Nathal E, Yasui N, Suzuki A and Hadeishi H. **Ruptured Anterior Communicating Artery Aneurysm Causing Bilateral Abducens Nerve Paralysis —Case Report—.** *Neurol Med Chir* 1992;32(1):17-20 Doi:10.2176/nmc.32.17